

Stress-Induced Cardiomyopathy Resulting from Abstinent Opioid Withdrawal

Kathryn Wieferich,¹ Andaleeb H Raja,¹ Nathan B Menke¹
¹University of Pittsburgh Medical Center, Pittsburgh PA USA

Introduction:

- Stress induced (Takotsubo) cardiomyopathy (CM) is a transient non-ischemic CM typically caused by an acute physical or emotional stressor
- This can present with EKG findings concerning for acute coronary syndrome, troponin elevation, and left ventricular wall motion abnormalities on echo that are not in the distribution of any coronary artery.^{1,2}
- There have been rare case reports of Takotsubo CM being triggered by opioid withdrawal

Case Report:

- 37 year old male with a history of daily oxycodone use and heroin/fentanyl abuse who presented to the ED five days after last taking oxycodone, in acute opioid withdrawal
- Patient was complaining of chest and abdominal discomfort on arrival
- He was agitated and combative, and required intubation and sedation
- Further evaluation revealed diffuse ST depressions on EKG consistent with NSTEMI and elevated troponins (initial 14; peak 44)
- Transthoracic echo revealed a dilated left ventricle with severely reduced systolic function (EF 15%)
- Left heart catheterization revealed normal coronary arteries and an EF of 15% with diffuse left ventricle hypokinesis sparing the apex
- Patient was diagnosed with non-ischemic CM
- He was started on aspirin, lisinopril, hydrochlorothiazide, and coreg and was extubated without complication
- On hospital day 3, patient left AMA and was lost to follow-up

Discussion:

- Takotsubo cardiomyopathy as a consequence of opioid withdrawal has only been described in rare case reports³.
- We believe abstinent opioid withdrawal was the etiology of our patient's CM based on his lack of coronary artery disease on catheterization and the diffuse hypokinesis noted on echo not in the distribution of any single coronary artery
- Although the syndrome typically presents with apical wall motion abnormalities, there are recognized variants which spare the apex and involve the mid-segments of the ventricle.²
- One theory regarding the etiology involves a catecholamine surge caused by an emotional or physical stressor which can be cardiotoxic and lead to depressed LV function.^{1,2}
- Opioid withdrawal may lead to a cardiotoxic catecholamine surge in some patients thus resulting in Takotsubo CM

Conclusion:

- Opioid withdrawal may trigger Takotsubo CM
- Although uncommon, it is a syndrome that should be kept in mind when evaluating opioid withdrawal patients presenting with cardiac symptoms

References

1. Pilgrim TM, Wyss TR. Takotsubo cardiomyopathy or transient left ventricular apical ballooning: a systemic review. *Int J Cardiol.* 2008; 124:283-292.
2. Prasad A, Lerman A, Rihal CS. Apical ballooning syndrome (Tako-Tsubo or stress cardiomyopathy): A mimic of acute myocardial infarction. *Am Heart J.* 2008; 155:408-417.
3. Saiful, FB, Lafferty J, Jun CH, Teli S, Duvvuri S, Khattri S, Bhat T. Takotsubo Cardiomyopathy due to iatrogenic methadone withdrawal. *Rev Cardiovasc Med.* 2011; 12(3): 164-167.
4. Cesário V, et al. Miocardiopatia de takotsubo num serviço de cardiologia. *Rev Port Cardiol.* 2012. <http://dx.doi.org/10.1016/j.repc.2012.01.018>.
5. Akashi YJ, Goldstein DS, Barbaro G, Ueyama T. Takotsubo Cardiomyopathy: A New Form of Acute, Reversible Heart Failure. *Circulation.* 2008; 118:2754-2762.

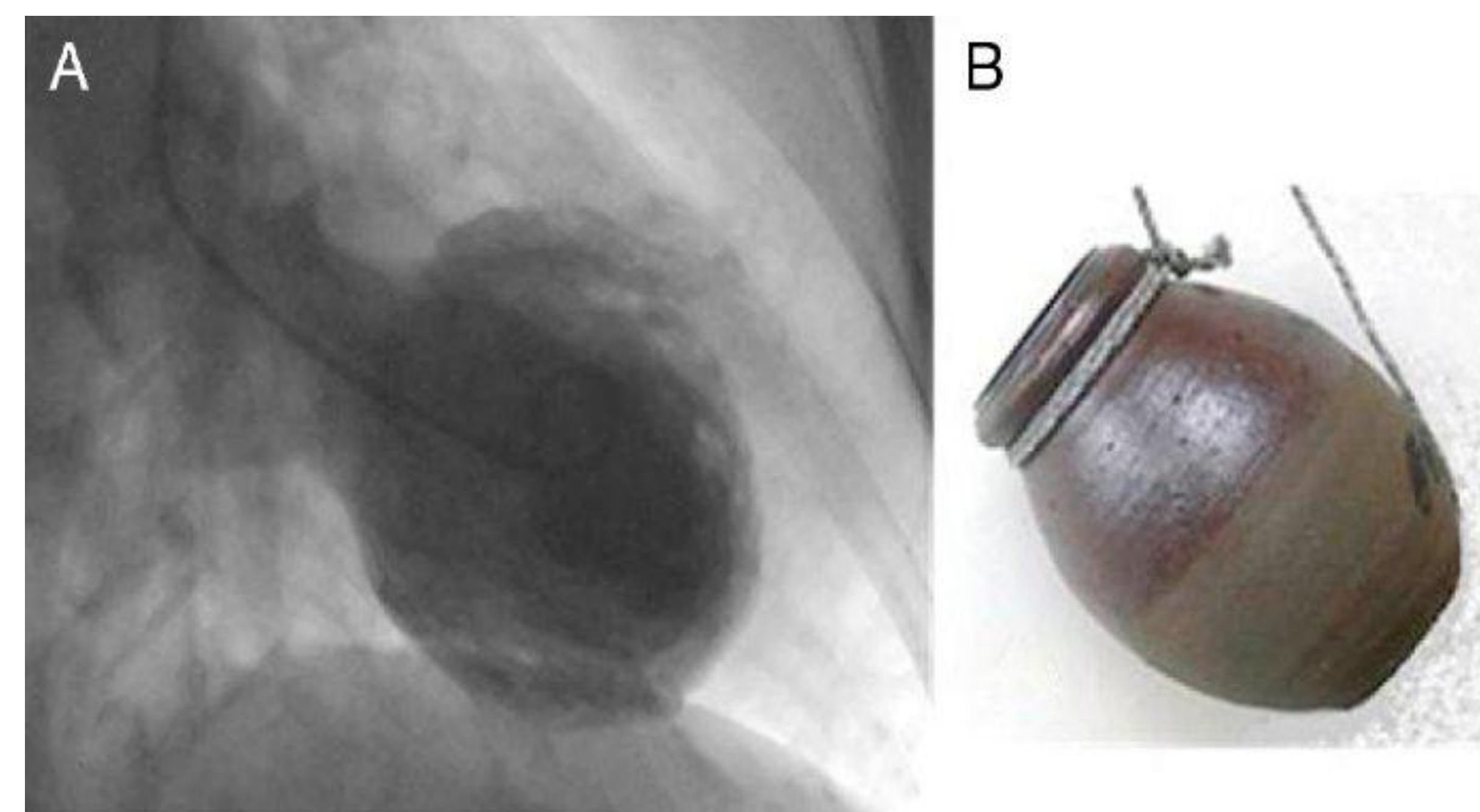


Figure 1. The typical appearance of the heart during systole in a patient with Takotsubo cardiomyopathy (A). This disorder is named for the Japanese octopus trapping pot (B)⁴

